



Hypertrophic Cardiomyopathy A Patient Perspective

Rick A. Nishimura, MD; Steve R. Ommen, MD; A.J. Tajik, MD



Affecting approximately one in every 500 people, hypertrophic cardiomyopathy is a unique disease in which there is an abnormal increase in the thickness of the heart muscle. Although the cause of hypertrophic cardiomyopathy was unknown in the past, it is now recognized that people with hypertrophic cardiomyopathy have a gene mutation that causes this abnormality. Most people with hypertrophic cardiomyopathy are relatively asymptomatic and able to maintain a normal lifestyle, but there are some who become severely limited by symptoms of shortness of breath and chest pain. There is also a small number of people with hypertrophic cardiomyopathy who may die suddenly. However, proper diagnosis and treatment of this disorder can relieve symptoms and prolong life.

Abnormalities in Hypertrophic Cardiomyopathy

In people with hypertrophic cardiomyopathy, the muscular wall of the main pumping chamber of the heart (left ventricle) is abnormally thickened (Figure 1). This increased thickness is called hypertrophy, and it usually involves the muscular wall between the right and left ventricles (the ventricular

septum), but it may occur in any part of the left ventricle.

The heart muscle is usually able to pump well despite the hypertrophy, and thus most people do not have limiting symptoms. However, for some people, the thickened heart muscle is abnormally stiff. Therefore, when the left ventricle fills with blood, the stiffness of the muscle increases the pressure inside the left ventricle, and this high pressure is reflected back into the lungs, causing symptoms of shortness of breath. In some cases, the increase in the thickness of the ventricular septum occurs just below the aortic valve and may block the normal blood flow out of the heart into the large blood vessel supplying blood to the rest of the body (the aorta). When the flow of blood in the aorta is impeded, the term hypertrophic obstructive cardiomyopathy is more accurately used. Obstruction of blood flow may cause symptoms of shortness of breath, chest pain, and dizziness with exertion. The thickening below the aortic valve may also disturb the function of a second valve, the mitral valve, which normally prevents backward flow of blood from the left ventricle to the left atrium. When there is distortion of mitral valve motion, the blood can move backward into the left

atrium, and the patient will experience shortness of breath.

Heart rhythm abnormalities can occur in people with hypertrophic cardiomyopathy. Atrial fibrillation is an abnormal heart rhythm in which the top part of the heart (the atrium) undergoes disorganized electrical activation and sends multiple, fast, irregular impulses to the left ventricle, so that the heart beats rapidly and irregularly, resulting in symptoms such as palpitations, shortness of breath, or decreased exercise capacity. Originating from the left ventricle, other more dangerous rhythms called ventricular tachycardia or ventricular fibrillation can result in sudden death.

Diagnosis of Hypertrophic Cardiomyopathy

The diagnosis of hypertrophic cardiomyopathy may be suspected on a routine examination, when either a heart murmur is heard or an abnormal electrocardiogram (ECG) is found. Patients with an obstruction from the thickened septum below the aortic valve may have a murmur that can be heard during examination (auscultation) of the heart. Because of the increased muscle thickness, abnormalities characteristic of hypertrophic

From the Mayo Clinic and Mayo Foundation, Rochester, Minn.

Correspondence to Rick A. Nishimura, MD, Mayo Clinic and Mayo Foundation, 200 First St, SW, Rochester, MN 55905. E-mail jhalling@mayo.edu (*Circulation*. 2003;108:e133-e135.)

© 2003 American Heart Association, Inc.

Circulation is available at <http://www.circulationaha.org>

DOI: 10.1161/01.CIR.0000097621.97566.96

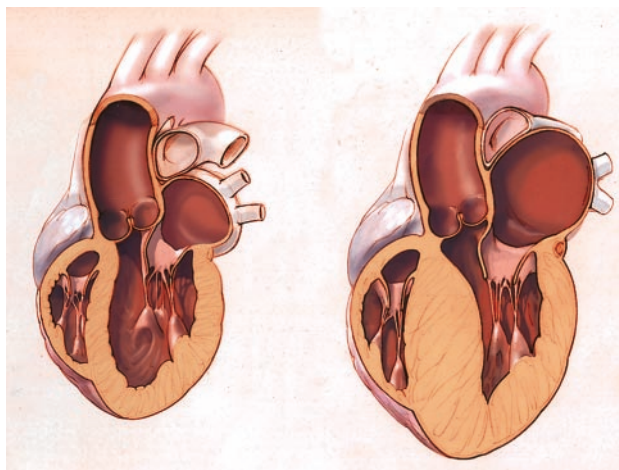


Figure 1. Schematic diagram of a patient with a normal heart (left) and a patient with hypertrophic cardiomyopathy (right). There is a marked increase in the thickness of the walls of the heart in the patient with hypertrophic cardiomyopathy.

cardiomyopathy will be evident on the ECG.

The diagnosis of hypertrophic cardiomyopathy can be confirmed with an echocardiogram, which uses ultrasound to show images of the beating heart. Images from the echocardiogram can show measurements of muscle thickness, the presence and degree of obstruction, valve motion, and blood flow. Once the diagnosis of hypertrophic cardiomyopathy is made, other tests may be performed to further determine the need for therapy. The patient may wear a Holter monitor, a portable device that records a continuous ECG, usually for 24 to 48 hours. Exercise testing can objectively measure a person's exercise tolerance, blood pressure, and heart rate and record any abnormal heart rhythms. In some patients, cardiac catheterization is required to measure the degree of obstruction and examine the status of the arteries that supply blood to the heart (the coronary arteries).

General Guidelines for People With Hypertrophic Cardiomyopathy

Most people with hypertrophic cardiomyopathy are able to live a normal life. People with hypertrophic cardiomyopathy, however, should not participate in strenuous activities, such as compet-

itive athletics, but may engage in mild aerobic healthy activity, such as a walking program. During strenuous exertion, the abnormally thick heart muscle may not be able to get enough oxygen from coronary blood flow, and dangerously abnormal heart rhythms may occur. People with hypertrophic cardiomyopathy should always keep themselves well hydrated, as dehydration can cause patients to have more symptoms. Antibiotics taken before dental or surgical procedures (infective endocarditis prophylaxis) should always be used to prevent infections of the heart.

Because hypertrophic cardiomyopathy is a genetic disorder, family members should undergo diagnostic screening with echocardiography. In young patients, the screening should be performed every 3 years; in adults, every 5 years. In the future, genetic analysis may be used in place of echocardiography to diagnose hypertrophic cardiomyopathy even before the increase in muscle thickness has developed.

Natural History

Most people with hypertrophic cardiomyopathy are able to maintain a normal lifestyle with a normal life span. Some may develop progressive symptoms, appearing at any age, which can change their life significantly. Very rarely, people with hypertrophic car-

diomyopathy die suddenly. Physicians now are able to identify predictors of those at greater risk so that appropriate treatment can be instituted.

Treatment of Hypertrophic Cardiomyopathy

A thorough medical examination is necessary to determine optimal treatment for people with hypertrophic cardiomyopathy. Treatment goals are to relieve symptoms and prevent sudden death in people at high risk. Therapy to relieve symptoms is aimed at decreasing obstruction and thus is effective in severe obstruction.

Medications

Medications can be used to decrease the contraction force of the heart and thus partially relieve the obstruction. Effective medications such as beta-blockers, calcium channel blockers, or disopyramide must be started slowly and under physician supervision. Because the goal of any therapy is to improve symptoms, medical therapy alone appears to be adequate in the majority of patients. In patients without obstruction, medications may be useful to slow the heart rate and allow the stiff heart muscle to relax better.

Pacemaker Therapy

In a subset of people with hypertrophic cardiomyopathy and obstruction, implantation of a permanent pacemaker has been shown to partially relieve the obstruction and to improve symptoms. Implantation of a permanent pacemaker is the least invasive of the treatment modalities used for patients with hypertrophic cardiomyopathy, but the overall success rate of a permanent pacemaker implantation is less than 40% to 50%. Therefore, permanent pacemakers are usually used in older individuals who do not wish to undergo the more invasive procedures. The recipient must understand that the quality of life provided by a pacemaker is far less than the quality of life that can be provided by the 2 other treatment modalities, surgical myectomy and septal ablation.

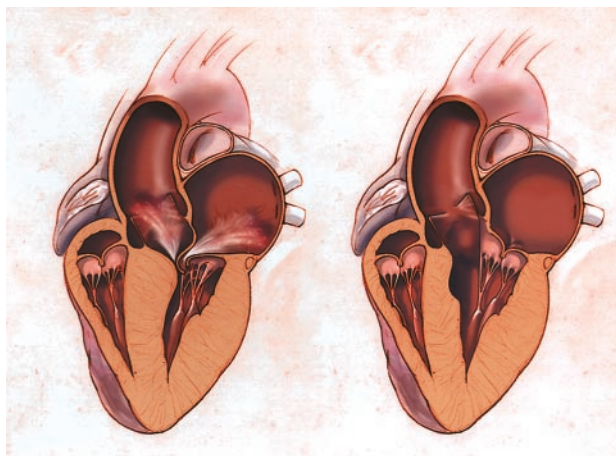


Figure 2. Patient before (left) and after (right) septal reduction therapy for hypertrophic cardiomyopathy. Before the septal reduction therapy, there is severe obstruction to blood flow going out into the body. The mitral valve is pulled against a thick septum and this can cause a leak of the mitral valve. After the procedure in which the septum has been removed or reduced, there is no longer any obstruction to outflow or leak of the mitral valve.

Surgical Myectomy

Septal myectomy is an open heart procedure in which the muscle of the septum blocking the flow of blood is surgically removed (Figure 2). This procedure requires surgical expertise and thus is performed mainly at centers (tertiary centers) that treat a large number of critically ill patients. Septal myectomy is considered by experts to be the best treatment (the “gold standard”) of patients with severe symptomatic hypertrophic cardiomyopathy and obstruction. The death rate due to the operation (operative mortality) in an otherwise healthy person is less than 1%. The thickened muscle does not grow back and more than 90% to 95% of patients who have this procedure are able to return to a normal lifestyle without recurrent symptoms. This procedure has been performed since the 1960s, and long-term follow-up after operation is excellent.

Septal Ablation

Septal ablation is a new, evolving treatment for people with hypertrophic

cardiomyopathy and obstruction in which a cardiologist purposefully destroys a small portion of the abnormally thickened heart muscle using a catheter threaded up through an artery from the leg. In this procedure, the small artery of the heart that supplies the thickened muscle at the region of the obstruction is identified and alcohol is injected into this artery. The alcohol causes a localized destruction of a portion of the thick heart muscle. With time, the muscle will shrink and scar, thus reducing the obstruction and improving symptoms (Figure 2). The success rate of this septal ablation procedure is less than that of septal myectomy because of difficulty in identifying the artery that supplies blood to the area of hypertrophy producing obstruction. In addition, there are potential complications of the procedure, such as heart block requiring a permanent pacemaker, a large amount of heart damage, and life-threatening rhythm problems. Patients who undergo this procedure must understand

that the long-term outcome is not yet known and there may be detrimental long-term consequences of the procedure that have not yet been realized. Nonetheless, if patients and family are well informed of these caveats, septal ablation may be an alternative for some patients to septal myectomy.

Prevention of Sudden Death in Hypertrophic Cardiomyopathy

A small subset of people with hypertrophic cardiomyopathy may experience sudden death, usually caused by abnormal heart rhythms (arrhythmias) in the heart’s electrical system. It is interesting to note that hypertrophic cardiomyopathy is the most frequent cause of sudden death in young athletes. However, the vast majority of people with hypertrophic cardiomyopathy will not be at risk for this catastrophic complication. Identification of risk factors is an important part of the evaluation of people with hypertrophic cardiomyopathy and requires an extensive history and several different cardiac tests. In patients who have been identified as having an increased risk of sudden death, implantation of a cardioverter-defibrillator can prevent this from occurring.

Conclusion

Hypertrophic cardiomyopathy is a hereditary disease entity that causes a severe increase in the thickness of the heart muscle. Although the majority of patients are asymptomatic and can lead a normal life, there are some who present with severe symptoms and some who are at increased risk for sudden death. A full medical evaluation at experienced treatment centers can determine appropriate therapies for improvement of symptoms and identify those patients who may be at risk for sudden death.